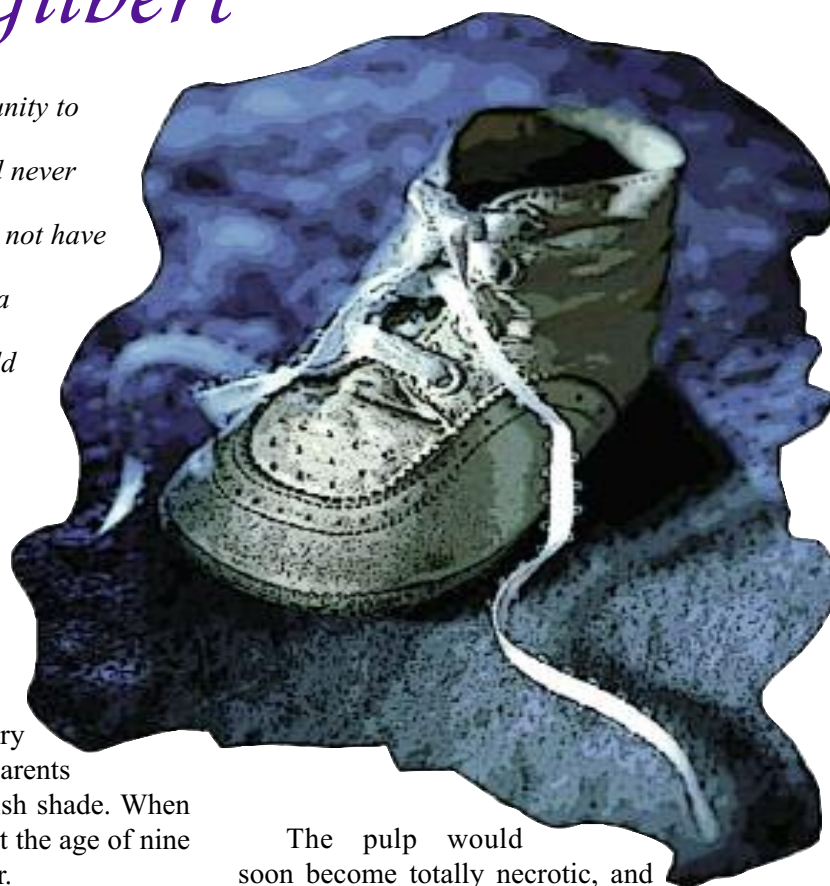


PRIMARY ANTERIOR PULPOTOMY

CONGENITAL DEFECT AND THE YOUNGEST PULPOTOMY CASE EVER REPORTED

Baby Gilbert

In 1957, I had the opportunity to perform an operation that had never been reported before and may not have been done since. I performed a pulpotomy on a nine-month-old baby boy.¹⁶



When Baby Gilbert's maxillary right central incisor erupted, his parents noticed that it was an unusual pinkish shade. When they brought the baby to our clinic at the age of nine months, the tooth was turning darker.

Clinical examination revealed that the central lobe of the tooth was incompletely formed and that the enamel was not supported by dentin. There was an opening from the incisal edge directly into the pulp. The pulp was adjacent to the enamel, which produced the pinkish color, and the opening allowed for direct contamination and degeneration of the pulp, which is why the tooth was getting darker. A vital pulp response was obtained with an explorer near the cervical line of the tooth.

Radiographs confirmed that the pulp chamber extended to the incisal edge of the tooth and that the root was only partially formed. There was no sign of a periapical lesion.

The pulp would soon become totally necrotic, and the chances of successful root canal treatment in an incompletely formed primary tooth in a nine-month-old child were not good. I explained to Gilbert's parents that if he lost the tooth, it could have an adverse impact on the child's speech, the growth and development of the maxilla, and equally as important, on Gilbert's psychological well-being during early childhood. The parents understood the situation, and the decision was made to try to save the tooth.

I performed a pulpotomy in the hospital under general anesthesia. The pulp was amputated using a sharp curette. Bleeding was controlled with cotton pellets, and Pulpdent Paste was applied directly over

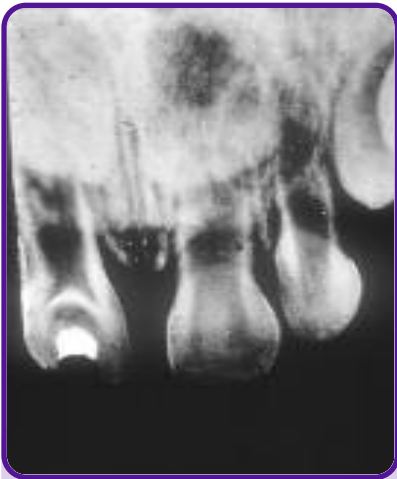

Figure BG1
Shows dense new dentin bridge and incompletely formed roots one month following pulpotomy on primary right central incisor.

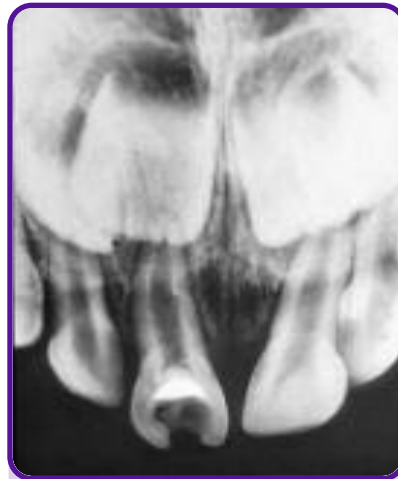


Figure BG2
Shows normal development of the pulp-tomized tooth more than six years later. Note complete root development.

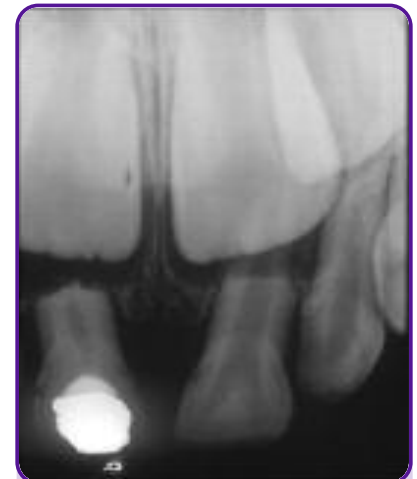

Figure BG3
Shows normal resorption of the roots of the pulp-tomized tooth.

the remaining pulp tissue. Zinc phosphate cement was used to seal the dressing in place and provide a supportive base for a self-curing resin restoration. Baby Gilbert showed no evidence of discomfort following the pulpotomy.

One month after the pulpotomy, the tooth was examined and radiographs were taken. A well-defined new dentin bridge was clearly visible (*BG1*). We followed the case for almost seven years, and the radiographs show that the root continued to develop at the same rate as the adjacent central incisor, indicating that the remaining pulp tissue was vital and capable of physiological function (*BG2*). The root also resorbed, as did the adjacent primary central incisor, showing normal biological growth, development and resorption (*BG3*).

For research purposes, we wanted to fully document this case by doing a histological examination of the tooth. The grateful parents were more than happy to oblige, and at the age of seven years three months, 6½ years following pulpotomy and shortly before the tooth would exfoliate on its own (and possibly get lost), the tooth was extracted.

Histological examination revealed a vital pulp completely enclosed in dentin, although containing several foci of inflammation (*BG4*). At the initial site of amputation a new dentin bridge had formed, re-enclosing the pulp in its own natural, protective chamber. The pulp tissue exhibited a prominent vas-



Figure BG4
Histological section shows dentin bridge and resorption of the root.

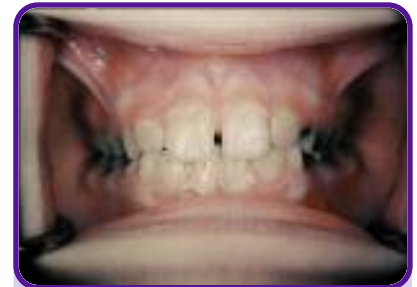

Figure BG5
Shows normally erupted permanent teeth with no defects.

cular component with many dilated vessels and perivascular infiltrations of leukocytes and plasma cells. The number of odontoblasts was reduced and one pulpal horn appeared to have a small intrapulpal abscess. The apex of the tooth demonstrated normal physiological resorption.

Localized intrapulpal abscesses are not uncommon. They can be caused by chemical, mechanical or bacterial invasion. It is also possible that stalactite extensions of new dentin formations after pulpotomy could impinge on areas of the pulp and deprive them of adequate circulation and essential nutrients. Such local abscesses can become completely walled off and may not affect the vitality of the remaining pulp tissue.

In this case, despite the evidence of degenerated tissue removed at the time of pulpal amputation, rapid formation of a new dentin bridge indicates that minimal pathology existed immediately following the pulpotomy.

When the permanent central incisors erupted, they were normal and without enamel defects (*BG5*).