

PERIAPICAL LESION WITH A PERFORATED FURCATION

Dr. Howard



I was playing golf with my friend Dr. Howard when he lamented that he was going to lose a tooth that was a terminal abutment for a four-unit bridge. His dentist had referred him to an endodontist who told him that the tooth was hopeless and would have to be extracted. I offered to look at his radiograph and give him a second opinion.

The radiograph showed a four-unit bridge with a large carious lesion under the crown on the lower left second molar (#18), which served as the terminal abutment (*HLI*). I suggested that he come to Boston for treatment, and we would try to save the tooth. If that failed, he could consider an implant.

I saw Dr. Howard in Boston on May 10, 1989. Upon initial evaluation, a fistulous tract could be seen near his lower left second molar. A gutta percha point was placed into the fistulous tract and a diagnostic radiograph was taken which showed the gutta percha point going to the apex of the tooth. The bridge was removed revealing considerable caries extending into the cervical area below the margin of the distal root. To further complicate the case, there was also furcation involvement.

The treatment plan was to negotiate the root canals, heal the periapical lesions with TempCanal, bicuspidize the tooth and preserve the roots for the terminal bridge abutment.

After removing the caries, one distal and two mesial canals were filed and reamed to a depth of 20 mm opening the canals to a #40 instrument. The canals were filled with Pulpdent TempCanal, temporary calcium hydroxide canal treatment paste, to disinfect the canals and stimulate healing of the periapical lesions and fistulous tract.

The old bridge would serve as the best temporary restoration; however, the margin on the molar tooth of the bridge was too short and would have to be extended to seal the cervical area of the molar.

In order to accomplish this, a cuff of gingival tissue was removed by electrosurgery to reduce the pocket depth and expose the roots. A #15 copper band was tightly fitted to the tooth at the gingival margin and trimmed to a height of 2-3 mm so that it could be attached to the existing bridge. Vertical slits were made perpendicular to the top edge of the band so that the band could be tapered inward to fit inside the crown. The molar crown of the existing bridge was filled with self-curing resin and resealed. The copper band, therefore, became attached to the existing crown and formed an extension of the crown, creating a new cervical margin (HL2).

I saw Dr. Howard again three weeks later on May 30, 1989. Oral examination revealed that the fistulous tract had healed, and a radiograph showed that the periapical lesions had already reduced in size. The TempCanal dressing was changed, and based on the favorable prognosis and the furcation involvement, the decision was made to bicuspidize the tooth. The roots were separated by cutting through the furcation from buccal to lingual and then circum-

scribing the roots with a pointed diamond, creating a channel for fitting a copper band.

In order to temporize the case, copper bands were fitted tightly to each root and attached to the existing crown as described above. The case was re cemented with PolyCarb WaterSet, a water activated polycarboxylate cement (HL3). Note how periapical healing has occurred.

Dr. Howard returned to Boston on August 28, 1989. At this visit the root canals were filled with Pulpdent Root Canal Sealer using the Pressure Syringe technique (HL4). Note that the periapical lesions are totally healed.

On August 29, 1989 final preparations were made and impressions were taken for a new bridge. The bridge was inserted on October 5, 1989.

Figure HL5 is a radiograph taken by Dr. Howard's dentist, on October 13, 1994, five years after the case was completed. The case looks great.

I played golf again with Dr. Howard in January 2002. He reports that he is comfortable and has had no problems whatsoever.

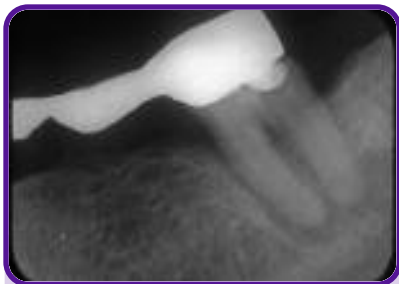

Figure HL1
Note carious lesion on the distal of the molar.

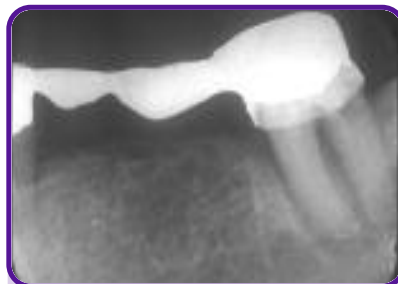

Figure HL2
Radiograph shows copper band attached to the crown and canals filled with Pulpdent TempCanal.

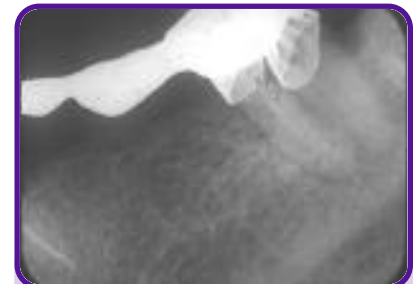

Figure HL3
Radiograph shows copper bands attached to the existing crown. Note periapical healing.

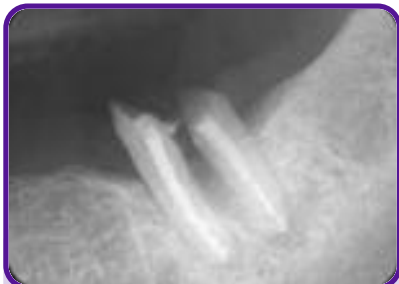

Figure HL4
Radiograph shows root canals filled with Pulpdent Root Canal Sealer and total healing of the periapical lesions.

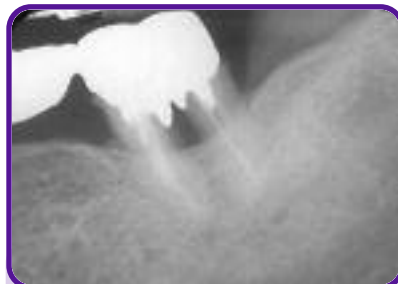


Figure HL5
Radiograph taken five years later.

Dr. Howard's case presented many challenges, but it confirms my belief that it is always worth trying to save that tooth.