

A NEW ONE-VISIT TREATMENT FOR PRIMARY TEETH WITH A PARULIS

Sara

In recent years, it occurred to me that since the healing of the parulis resulted from treating the root canals of primary teeth with TempCanal, it might not be necessary to renegotiate the canals and fill them with Pulpdent Root Canal Sealer. I decided to study this further.

I began to treat these cases with a one-visit procedure. After cleaning the canals, I filled them with Pulpdent Paste, TempCanal or Multi-Cal and placed a final restoration at the same visit. After following many such cases for several years, it is apparent to me that this one-visit technique is all that is necessary in most cases.

I have observed that the roots resorbed and the teeth exfoliated in the normal manner. I have also noted, however, that those teeth that had been treated for periapical lesions or furcation radiolucencies with a parulis often exfoliate sooner than their counterparts. I have been able to follow many of these cases, and I have seen no adverse effect on the permanent teeth.

However, if there is lot of pus draining through the canals, this one-visit technique is not indicated. In these cases, leave the tooth open until the pus is under control, which often occurs overnight. Should complications occur, the patient can be placed on an antibiotic, or extraction may be required. However, if three-quarters or more of the roots have resorbed, simply remove the tooth.

I began to treat these cases with a one-visit procedure.

Since this one-visit procedure was a new technique and was not the standard practice, I asked one of our postdoctoral students, Dr. Nooruddin Pradhan, to do a study using this procedure in fulfillment of the research requirements for his Master of Dental Science degree in Pediatric Dentistry.

The purpose of this study was to determine if a one-visit calcium hydroxide pulpectomy could be used to cure an abscessed primary molar with a parulis. This would avoid the necessity of renegotiating the canals and obturating them with sealer only, which is a two-visit procedure.

To help establish the effectiveness of the one-visit calcium hydroxide pulpectomy, without surgical intervention, the parulis was left untouched and was not drained.

Dr. Pradhan conducted the initial study while at Tufts from 1992-1993, and he continued the study for several years when he returned home to Pakistan. His letter to me dated May 5, 1996 reporting on

twenty-three cases, all of which were successful, appears below along with the case history and photographs of his nine-year-old patient, Sara. Dr. Pradhan reported to me that none of these twenty-three cases required anesthesia.

Sara had a parulis of the mandibular right primary second molar (*PRAD1*). After complete debridement of the canals, they were filled with TempCanal and a final restoration was immediately placed.

At the end of one week, there was approximately a 75% improvement and the patient was comfortable. A photograph taken three months later shows complete healing of the soft tissue (*PRAD2*). *Figure PRAD3* is a radiograph taken at the same visit showing the erupting second bicuspid. Dr. Pradhan reported that Sara remained free of pain with normal mastication until the tooth exfoliated. A space maintainer was never required.

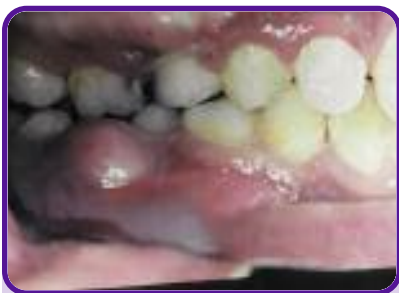

Figure PRAD1
Photograph showing parulis.

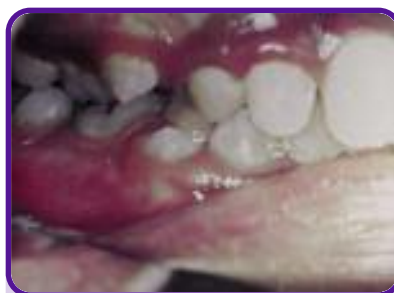

Figure PRAD2
Shows parulis healing without surgery.

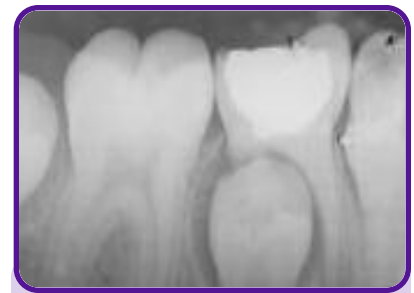

Figure PRAD3
Shows erupting second bicuspid.

Dr. Pradhan further reported to me that none of these twenty-three cases required anesthesia.

**ALVI DENTAL HOSPITAL
23 B Sindhi Muslim Society Karachi 74400**

May 5, 1996


Dr. Harold Berk
Clinical Professor
Department of Pediatric Dentistry
Tufts University
School of Dental Medicine
Boston, MA 02111

Dear Dr. Berk:

Hope you and your family be in the very best of health and happiness. I just don't know where to begin from, as I have a lot to say. I have been working on our project of "Effect of CaOH in primary teeth with abscess and parulis," I just tell my patients that this is a magic medication. I have done almost 23 cases and there has not been any failure so far, huge abscesses have resolved in a week to ten days time.

One of my patients, an eight-year-old girl, reported with a pedunculated growth related to infected mandibular primary right second molar, and the parents were very concerned, as they were advised on getting it excised. They came to me for a specialist opinion, and I told them about this magic medication and excellent results. I did one visit pulpectomy with calcium hydroxide medication. Within one week there was 50% improvement and by the third week the growth was completely gone, so I think you should realize what Pulpdent is producing.

Sincerely,



Nooruddin Pradhan

Dr. Nooruddin Pradhan
Specialist in Pediatric Dentistry &
Temporomandibular Joint (TMJ) Disorders
B.D.S., M.S. (U.S.A.)