



PART ONE

Early Pulp Studies and Histology

PART ONE
EARLY PULP STUDIES AND HISTOLOGY

INTRODUCTION	3
CALCIUM HYDROXIDE FOR VITAL PULPOTOMY	4
CALCIUM HYDROXIDE IN AQUEOUS METHYLCELLULOSE VS. CALCIUM HYDROXIDE AND WATER	
CALCIUM HYDROXIDE FOR CAVITY LINING	8
CALCIUM HYDROXIDE FOR DIRECT PULP CAPPING	10
TREATING LARGE EXPOSURES	10
TREATING SMALL EXPOSURES	12
FACT VS. FOLKLORE - DISPELLING MYTHS	13
CALCIUM HYDROXIDE FOR PULPAL CURETTAGE	14
REFERENCES	15

EARLY PULP STUDIES AND HISTOLOGY

INTRODUCTION

The 1950s and 1960s have been referred to as the “pulp biology years,” and it was during this period that we gained a great deal of our knowledge about the dental pulp.

Prior to that, our knowledge was limited, and with the exception of a small group of researchers, the concept of vital pulp therapy was virtually unknown. Investigators experimented with various materials and techniques in an attempt to understand how the pulp behaved and how best to protect it.

When Helmut Zander came to Tufts Dental School in Boston in 1944, we renewed our friendship and continued our research in vital pulp therapy. I had been experimenting with a mixture of silver nitrate, zinc oxide and eugenol as a pulpal dressing for primary teeth, and Dr. Zander convinced me that calcium hydroxide was the pulpal dressing of choice.

We would make a paste of calcium hydroxide powder and water, place it over the radicular pulp tissue after amputating the coronal pulp, and gently tamp the dressing to place with cotton, which also removed excess water. A thin layer of wax was then placed over the dressing prior to placement of a hard base of zinc phosphate cement. The rationale for the wax was to separate the dressing from the cement and prevent the acid in the cement from neutralizing the calcium hydroxide. The tooth was then ready to receive a final restoration.

This technique was cumbersome, and I began to look for other vehicles to create the calcium hydroxide paste. I tried glycerin, petroleum gel, Aquaphor, olive oil and numerous other resins and concoctions before I fell upon methylcellulose, which proved to be the perfect vehicle for the calcium hydroxide pulpal dressing and allowed me to develop a vital pulpotomy technique that would produce consistent results.

CALCIUM HYDROXIDE FOR VITAL PULPOTOMY

Vital Pulpotomy

The amputation of the entire coronal pulp followed by the application of a dressing to the radicular pulp tissue in an attempt to maintain the vitality of the pulp, stimulate new dentin bridge formation, and protect the pulp from additional irritation.

CALCIUM HYDROXIDE IN AQUEOUS METHYLCELLULOSE VS. CALCIUM HYDROXIDE AND WATER

In 1945,

1945

Dr. Helmut Zander and I conducted our first comparative pulpotomy studies using calcium hydroxide in aqueous methylcellulose.

These studies were conducted initially on dogs

and later on human teeth that were to be extracted

for orthodontic and prosthodontic purposes.

In our dog studies, we amputated the coronal pulp tissue and treated the radicular pulp with dressings of calcium hydroxide in aqueous methylcellulose, calcium hydroxide in water, and zinc oxide-eugenol. We were surprised to learn that we achieved superior results with calcium hydroxide in aqueous methylcellulose.

Histological evaluation after two months indicated that this new formulation, which is now called Pulpdent Paste, stimulated more rapid healing with the formation of regular tubular dentin (PS1). Calcium hydroxide in water produced a new dentin bridge, but without the maturity seen in the histological section with methylcellulose (PS2). Zinc oxide and eugenol, which was used as a control, produced inflammatory tissue without dentin bridge formation (PS3).

Calcium Hydroxide in Aqueous Methylcellulose

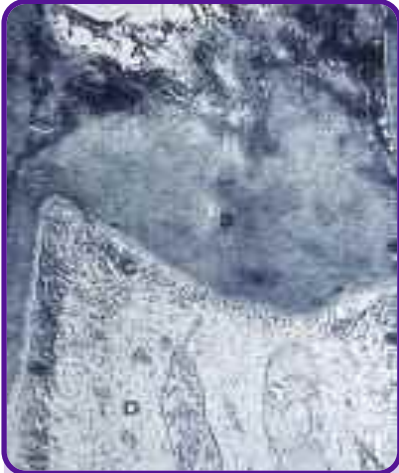

Figure PS1
Histological section of a dog's tooth shows healing two months after amputation of the coronal pulp and treatment with calcium hydroxide in aqueous methylcellulose (Pulpdent Paste). Note the density of the new dentin bridge with the formation of regular tubular dentin. These results are far superior to those shown in Figure PS2.

Calcium Hydroxide and Water



Figure PS2
Histological section of a dog's tooth shows healing two months after amputation of the coronal pulp tissue and treatment with calcium hydroxide and water. There is favorable organization of the odontoblasts, but regular tubular dentin is just beginning to form.

Zinc Oxide-Eugenol

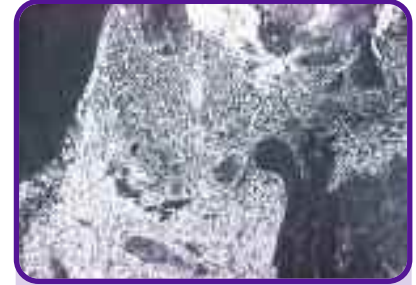

Figure PS3
Histological section of a dog's tooth two months after amputation of the coronal pulp tissue and treatment with zinc oxide-eugenol shows no dentin bridge formation and a considerable inflammatory lesion of the coronal portion of the pulp.

After these initial pulp studies, we proceeded with comprehensive studies on dentin bridge formation in human teeth that were scheduled for extraction, and we compared them with our findings in dogs. Teeth were sectioned at various intervals and the healing process was carefully observed.

Figures PS4 and *PS5* are histological sections of a dog's tooth and a human tooth 24 hours after pulpal amputation and treatment with Pulpdent Paste. A dense line of demarcation can be seen in both sections. The line of demarcation is where the new dentin bridge begins to form.

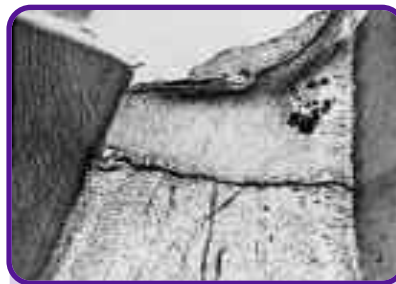

Figure PS4
Histological section of a dog's tooth 24 hours after pulpal amputation and treatment with Pulpdent Paste. Note the dense line of demarcation, which Zander referred to as calcium proteanate precipitate, to which the undifferentiated mesenchymal cells line up and act as odontoblasts.

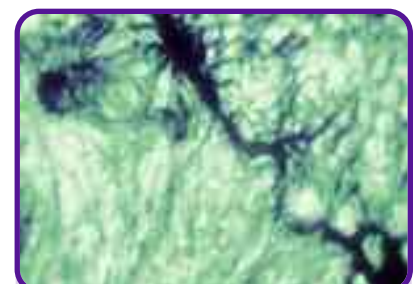


Figure PS5
Histological section of a human tooth 24 hours after pulpal amputation and treatment with Pulpdent Paste. Note the line of demarcation, which is the same as in the dog's tooth in Figure PS4.



Figure PS6
Shows a human tooth two weeks following pulpal amputation and treatment with Pulpdent Paste. Note the irregular dentin and the beginning formation of the odontoblastic layer.

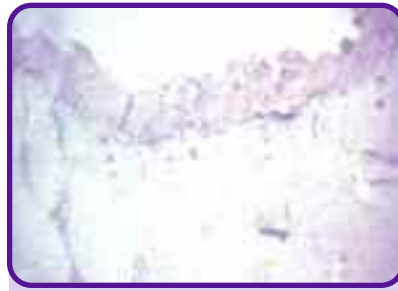

Figure PS7
Shows a human tooth three weeks following pulpal amputation and treatment with Pulpdent Paste. Note the organized odontoblastic layer and the beginning formation of regular tubular dentin.



Figure PS8
Shows regular tubular dentin being formed four weeks after pulpal amputation and treatment with Pulpdent Paste.

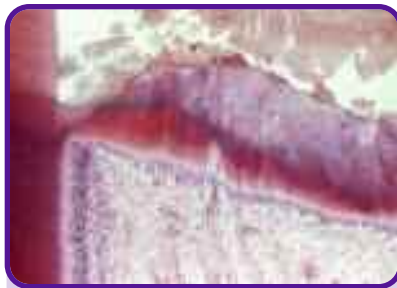

Figure PS9
Shows regular tubular dentin and Korpfs fibers two months following pulpal amputation and treatment with Pulpdent Paste.



Figure PS10
Shows a mature dentin bridge five months following amputation.

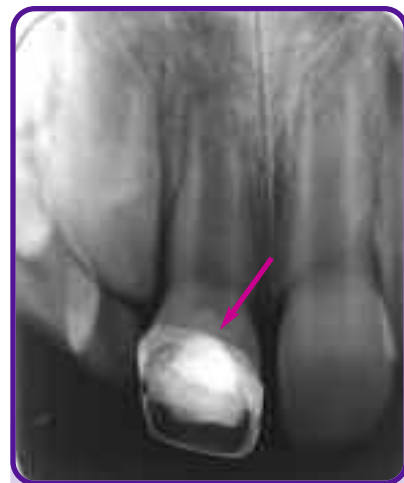

Figure PS11
Shows new dentin bridge formation two weeks following pulpotomy and treatment with Pulpdent Paste in tooth #8.

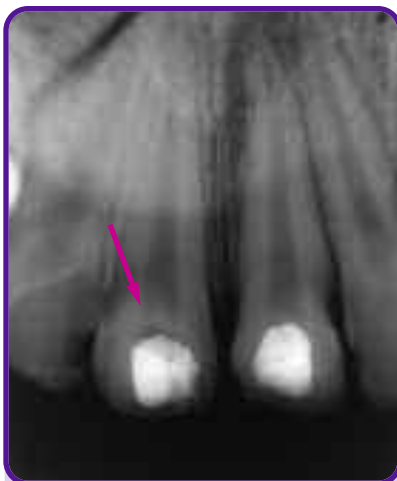

Figure PS12
Shows new dentin bridge formation four weeks following pulpotomy and treatment with Pulpdent Paste. Note the density of the new dentin bridge in tooth #8. Tooth #9 will require root canal therapy.

Figures PS6 - PS10 are histological sections showing the healing process from two weeks to five months. After two weeks, we can see the irregular dentin and the beginning formation of the odontoblastic layer (*PS6*). After three weeks we see the organization of the odontoblastic layer and the beginning formation of regular tubular dentin (*PS7*). Our four-week section shows regular tubular dentin forming (*PS8*), and after two months, Korpfs fibers have formed (*PS9*). Our histological section after five months shows a complete new dentin bridge (*PS10*).

It is interesting to note that the formation of the new dentin bridge can also be seen radiographically as early as two weeks after amputation. *Figures PS11* and *PS12* show a new dentin bridge forming two and four weeks, respectively, following pulpotomy and treatment with Pulpdent Paste.

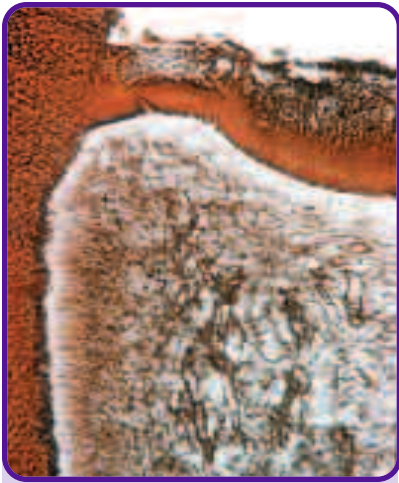

Figure PS13
Shows new dentin bridge formation, odontoblasts and Korpfs fibers two months following pulpotomy on a human tooth and treatment with Pulpdent Paste.

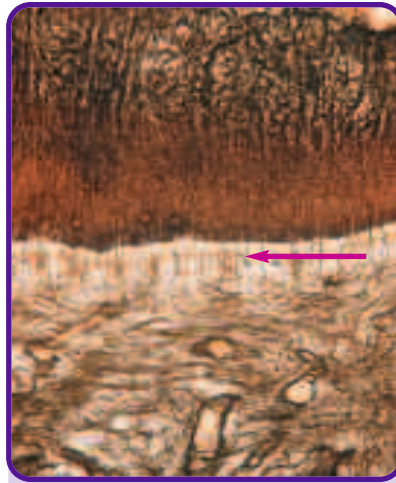


Figure PS14
This is a high power section of PS13 that distinctly shows the Korpfs fibers being incorporated in the formation of the regular tubular dentin by the odontoblasts.

Our histological section of a human tooth two months following pulpotomy, stained with silver after two months, shows in great detail new dentin formation with odontoblasts and Korpfs fibers (*PS13 & PS14*). In the organization of the blood clot, the undifferentiated mesenchymal cells organized and acted as odontoblasts, laying down normal tubular dentin. It was fascinating to see that the new tubular dentin was formed in the exact same way that dentin is initially formed in the embryonic stage of tooth development.

The enhanced healing with Pulpdent Paste is most likely attributable to several factors:

- *Calcium hydroxide is not soluble in water, and it is difficult to handle and apply evenly. The addition of an aqueous solution of methylcellulose creates a homogeneous and cohesive paste that has the added advantage of adhering to the pulp tissue and the remaining dentin.*
- *The methylcellulose holds the calcium hydroxide in suspension and keeps it from drifting into the stroma of the pulp, thus preventing unwanted stalactite and stalagmite calcifications that have been shown to result in pulpal necrosis and internal resorption.*
- *The methylcellulose acts as a buffer, thus creating a mild irritation rather than a harsh insult, such as that which occurs when calcium hydroxide powder is placed directly on the pulp. Furthermore, methylcellulose is basically inert and does not affect the pH of the calcium hydroxide.*

CALCIUM HYDROXIDE FOR CAVITY LINING

Cavity Lining

The application of a dressing on the pulpal floor to protect the pulp from chemical irritation caused by filling materials and to stimulate the formation of sclerotic and reparative dentin.

During those early years, it was standard practice to use silicate cement as a dental filling material. It was noted, however, that there was considerable pulpal necrosis, even after filling small cavities with silicates. Many researchers were investigating the causes, and in 1945, Zander published his findings that the acids in silicate cements caused necrosis of the pulp.¹ In 1950, Zander, Glenn and Nelson reported that the chemical irritation from silicate cements could be controlled by placing a calcium hydroxide liner on the dentin adjacent to the pulp.^{2,3}

As a result of this research, I modified the Pulpdent Paste formulation and developed Pulpdent Cavity Liner, a fluid calcium hydroxide in aqueous methylcellulose preparation that was easy to apply to the dentin and dried quickly, leaving a chalky white protective layer that occupied virtually no space. This formulation, with pH>12, neutralizes the acids and other irritants in cements and dental filling materials, but does not interfere with their setting characteristics or with the seating of crowns and inlays.

The following histological sections from my early research with Helmut Zander revealed normal healthy pulps, free from inflammatory response, after application of Pulpdent Cavity Liner under silicate restorations.^{4,5} Silicate cement was chosen for these studies because of its known irritation to the dental pulp.

Figure PS15 is a histological section of a dog's tooth ten weeks following treatment with Pulpdent Cavity Liner. A large cavity had been prepared on the labial aspect, penetrating into the dentin, prior to the placement of Pulpdent Cavity Liner and silicate cement. Note that there is no irritation to the pulp, indicating complete protection from the filling material.

Figure PS16 is a histological section of a human tooth two months following treatment with Pulpdent Cavity Liner. The tooth was restored with silicate cement. Note that there is no inflammatory reaction.

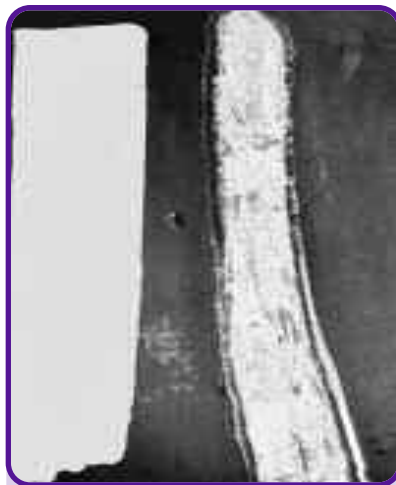

Figure PS15

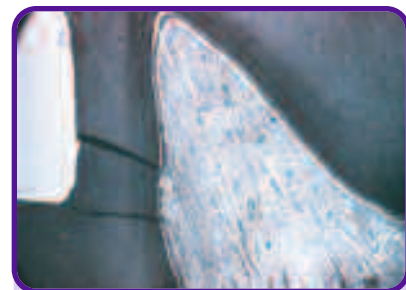

Figure PS16

SCLEROTIC AND REPARATIVE DENTIN

When dentin is exposed due to dental caries, mechanical intervention or traumatic injury, nature responds by forming sclerotic and reparative dentin. This is part of the natural healing process, and this is nature's way of desensitizing the dentin and protecting the pulp.

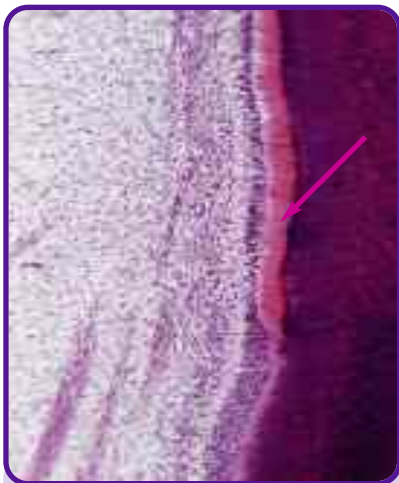
Sclerotic dentin is the calcification of the dentinal tubules adjacent to the cavity preparation, which may be formed by the reaction of Tomes' fibers within the dentinal tubules.⁶ With the use of Pulpdent Cavity Liner, Mjor has noted that the density of the dentin increased by 25% within 15 days.⁷

Reparative dentin is the formation of new dentin adjacent to the pulp, which is created by the odontoblasts and begins to form approximately 20-30 days after the insult to the pulp. About 1.5 microns of reparative dentin are formed per day for a period of 30-60 days.^{6,8,9}


Figure PS17 is a histological section from my pulp studies showing the formation of reparative dentin two months following treatment with calcium hydroxide. The freshly cut dentin was coated with Pulpdent Cavity Liner prior to the placement of the restoration.

One of my postdoctoral students in the Harvard/Forsyth Endodontic Program was fascinated with the histological results that I showed in my lectures on vital pulp therapy. He decided to do his postgraduate thesis on this subject.¹⁰

Figure PS18 is a histological section from his thesis, stained with sudan black, showing the formation of sclerotic dentin two months after applying Pulpdent Cavity Liner to freshly cut dentin.



PS17
Histological section from my pulp studies showing the formation of reparative dentin two months following treatment with Pulpdent Cavity Liner.



PS18
Histological section stained with sudan black showing the formation of sclerotic dentin two months after applying Pulpdent Cavity Liner to freshly cut dentin.
(Courtesy of Dr. M. Levine)

CALCIUM HYDROXIDE FOR DIRECT PULP CAPPING

Pulp Capping

The application of a dressing to the exposed pulp tissue of a vital tooth in an attempt to maintain the vitality of the pulp and to stimulate new dentin bridge formation.

TREATING LARGE EXPOSURES

Many discoveries in medicine, science and other fields are made by accident. In 1955, I continued my pulp studies at the National Institutes of Health when I accidentally discovered that even the largest possible pulpal exposure could heal with complete dentin bridge formation if properly treated with Pulpdent Paste, the original premixed calcium hydroxide methylcellulose pulpal dressing.

I had stopped at the front entrance of the NIH to pick up some research material when the security guard, who was thirty-six years old, told me that he had a severe toothache and asked if I would extract the tooth. I told him to come to the clinic immediately, and upon evaluation, I could see that his maxillary right and left first molars (#3 and #14) were severely decayed. I was anxious to include an adult in my pulp study, and I asked him if he would be willing to participate and postpone the extractions for four to eight weeks if I could eliminate the pain. I was very pleased when he agreed to do so.

I dissected off the entire roofs of the pulp chambers of both teeth leaving the odontoblastic layer intact (except where inadvertently penetrated with the bur while dissecting off the overlying dentin). Pulpdent Paste was placed onto the pulp tissue, sealed in place with zinc

phosphate cement, and the teeth were restored with aluminum shell crowns, since they would soon be extracted for sectioning.

After one month I extracted one of the teeth, and after two months I extracted the other one. Histological sections were prepared in accordance with the protocol for my pulp study.

When the histological sections came back from the laboratory, I was astonished to see new roofs of dentin with healthy pulps (*PS19 and PS20*). A note was attached asking: "Why were these teeth extracted?" The teeth had healed completely. This is how I discovered that even the largest exposure can be treated successfully and that a toothache is not necessarily a contraindication for direct pulp capping.

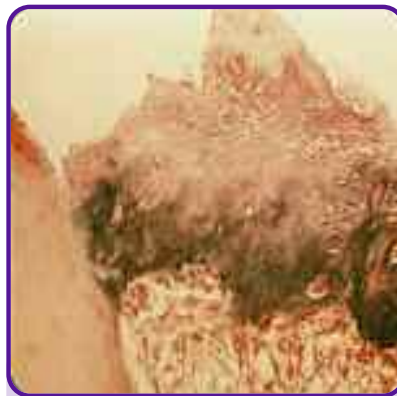

Figure PS19
Histological section of NIH security guard's extracted maxillary right first molar (#3) one month following removal of the roof of the pulp chamber and treatment with Pulpdent Paste. Complete healing of this very large exposure was a breakthrough in our research on pulp capping. (Histological section prepared by Harold Stanley.)

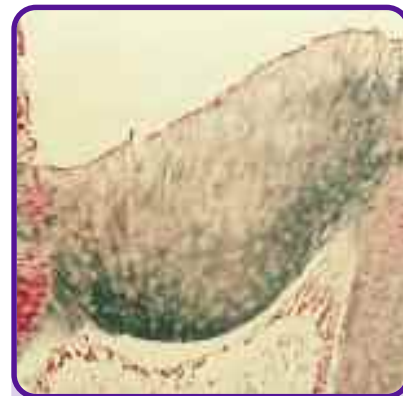


Figure PS20
Histological section of NIH guard's maxillary left first molar (#14) two months following pulp capping with Pulpdent Paste shows total healing with the formation of regular tubular dentin. (Histological section prepared by Harold Stanley.)

Many discoveries in medicine, science and other fields are made by accident.

While at the National Institutes of Health, I had the opportunity to include in my pulp study a twelve-year-old boy whose lower second molar was scheduled for extraction for orthodontic purposes. Again, I deliberately dissected off the entire roof of the pulp chamber and placed Pulpdent Paste against the exposed pulp. I sealed the Pulpdent Paste in place with zinc phosphate cement and amalgam, and one month later the tooth was extracted. A histological section of the tooth showed complete new dentin bridge formation and a healthy pulp (*PS21*).

Figure PS22 is a photomicrograph of an extracted bicuspid of another twelve-year-old boy two weeks following removal of the entire roof of the pulp chamber and placement of Pulpdent Paste as the pulpal dressing. The tooth was extracted for orthodontic purposes. The orthodontist was a bit impatient and did not want to wait any longer, but even after just two weeks the histological section shows the initial formation and organization of the new dentin bridge.

An interesting question arose at this time. When removing the roof of the pulp chamber, did the odontoblastic layer remain attached to the pulp, or was it removed with the overlying dentin? Our research indicated that virtually all the odontoblasts remained attached to the pulp, although we did find a few attached to the dentin. These results can be seen in *Figures PS23 and PS24*.

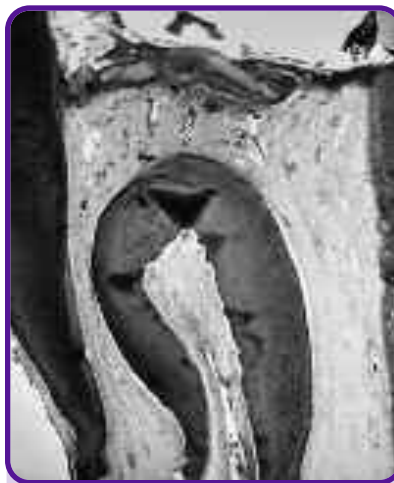

Figure PS21
Histological section shows new dentin bridge one month following removal of entire roof of the pulp chamber and treatment with Pulpdent Paste.

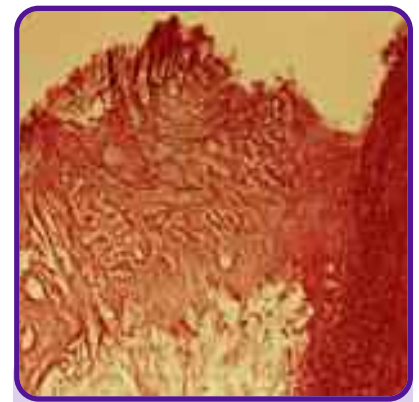


Figure PS22
Shows odontoblastic organization and irregular dentin two weeks following removal of entire roof of pulp chamber and treatment with Pulpdent Paste.

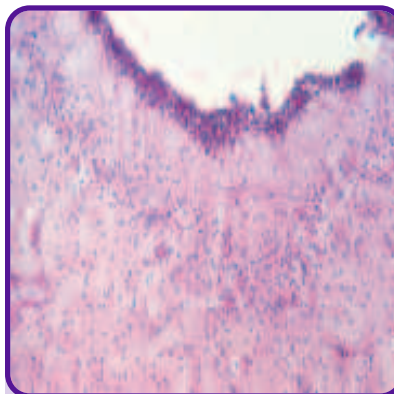


Figure PS23
Histological section of a permanent tooth after removal of the roof of the pulp chamber, which shows the odontoblastic membrane attached to the pulp, except where it was inadvertently penetrated while dissecting off the overlying dentin.

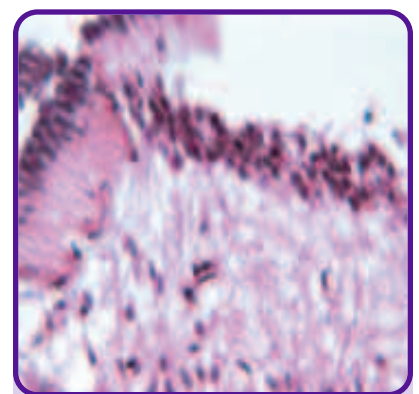


Figure PS24
Shows the odontoblastic layer remaining attached to the pulp of a primary tooth following the removal of the overlying dentin.

TREATING SMALL EXPOSURES

To achieve the highest rate of success in the direct pulp capping technique, *the calcium hydroxide paste should be placed in direct contact with the pulp in order to stimulate healing and new dentin bridge formation.*⁵ In cases with only a tiny exposure, it may be necessary to enlarge the exposure site so that the calcium hydroxide can come into direct contact with the pulp.

Figure PS25 is a histological section showing a tiny pulpal exposure. Notice how the pulp tissue has retracted from the exposure site. Placing the calcium hydroxide dressing over this exposure may result in

a failure because the dressing will not be in direct contact with the pulp. Furthermore, debris and contaminants could be trapped under the overhanging dentin at the exposure site, and this could lead to failure.

In treating cases such as this, it is best to dissect off the overhanging dentin, as illustrated in *Figure PS26*. This will enlarge the exposure sight and enable the calcium hydroxide dressing to come into direct contact with the pulp (*PS27*). When the tooth is prepared for pulp capping in this manner, healing will almost always occur.



Figure PS25
Note retraction of the pulp tissue at the exposure site. When treating tiny exposures, it can be difficult to place the calcium hydroxide dressing in direct contact with the pulp.



Figure PS26
Enlarge the exposure site by removing the overhanging dentin.



Figure PS27
Shows the overhanging dentin removed.

FACT VS. FOLKLORE - DISPELLING MYTHS

There are misconceptions about pulp capping that relate to the size of the exposure, whether to bring blood to the exposure site, the effect of saliva contamination, the age of the patient, the color of the dentin, and whether to place a temporary or permanent restoration.

Size of Exposure

Perhaps the greatest misconception about direct pulp capping has to do with the size of the exposure. The fact is that while it is possible for the exposure site to be too small to achieve the highest success rate, there is no limit to how large an exposure can be for successful pulp capping.

Bringing Blood to the Exposure Site

It is detrimental to intentionally bring blood to the exposure site in vital teeth. Pulpal exposure is often encountered without bleeding. Intentionally puncturing the odontoblastic membrane to draw blood can induce an inflammatory response and create a site for bacterial contamination of the pulp. Sometimes, because of the structure of the pulp, and perhaps the ischemic effect of local anesthesia, a perfectly normal pulp will not bleed when slightly penetrated. Therefore, a lack of bleeding is not a contraindication for direct pulp capping in vital teeth. Research shows that even though the pulp itself is vascular, the odontoblastic layer is relatively avascular.¹¹

Saliva Contamination

Saliva contamination in the stroma of the pulp is a serious matter; however, superficial saliva contamination is not a critical factor if properly treated. If saliva inadvertently contacts the exposure site, thoroughly clean the site with sodium hypochlorite, or any other nonirritating agent, and flush with distilled water, sterile saline solution, or apply 2% chlorhexidine and air dry, before applying the calcium hydroxide dressing.

I investigated these factors as part of my pulp studies at the National Institutes of Health, and they led to the following conclusions, which have been corroborated by half a century of clinical evidence.

Age

Age is not a critical factor. We have seen the same high success rate with patients of all ages. The volume of pulp tissue remaining to aid in the healing process is a more important criterion than the age of the patient.

Color of Dentin

We now have sufficient evidence that discolored dentin is not always infected and that light or normal colored dentin is not always free of bacteria.^{12,13} The color of the dentin, therefore, is not a valid criterion. The hardness of the dentin and resistance to cutting with a sharp instrument are more important indicators. SNOOP or your preferred caries detecting dye can also be used to identify infected dentin.

Placing Temporary vs. Permanent or Permanent Type Restorations

It has been our experience that the less we disturb the healing process, the better chance we have of success. I do not use temporary restorations, such as temporary stopping materials or zinc oxide-eugenol cements, after vital pulp therapy. Temporaries too often become loose or lost, and this increases the chances for contamination. The restoration should stay in place for approximately three months to allow for total healing to occur, and for this reason a more permanent type restoration is indicated. Creating a seal so that bacterial contamination cannot occur is the best assurance for success.¹⁴ Bacterial contamination is the major cause of failure.

CALCIUM HYDROXIDE FOR PULPAL CURETTAGE

Pulpal Curettage (partial pulpotomy)

The amputation of part of the coronal pulp tissue followed by the application of a dressing at the amputation site in an attempt to maintain the vitality of the pulp, stimulate new dentin bridge formation, and protect the pulp from additional irritation.

Although we were having considerable success in our pulp studies at the National Institutes of Health, we still could not understand why some seemingly routine pulp cappings failed.

To further investigate this matter, we performed pulp cappings and pulpal curettage on the coronal portions of anterior teeth and the pulpal horns of posterior teeth. We learned over time that if the pulp is narrow at the exposure site, calcification and dentin bridge formation can restrict the blood circulation to the coronal pulp tissue, resulting in pulpal necrosis. Therefore, pulpal curettage is preferred to direct pulp capping in those clinical situations where the volume of pulp tissue is insufficient and the blood supply may become inadequate to sustain the vitality of the pulp.

Figure PS28 is a photomicrograph of a tooth extracted for orthodontic purposes two months following labial pulp capping using Pulpdent Paste as the pulpal dressing. This is a borderline case, and although it was successful, our research taught us that to achieve the highest rate of success, pulpal amputation is recommended in cases such

as this, not pulp capping. There is too great a chance that the new dentin bridge will impinge on the circulation to the incisal pulp tissue, leading to pulpal necrosis, and therefore, pulpal curettage is the treatment of choice.

Figure PS29 shows a pulpal amputation of the incisal portion of an anterior tooth two months following amputation and treatment with Pulpdent Paste. By removing the incisal pulp tissue, there is no chance that the blood supply will be restricted by calcification and new dentin bridge formation. The blood circulation is unimpeded and healing will occur rapidly and consistently. Pulpal amputation is the treatment of choice and will produce the highest rate of success.¹⁵

Figure PS30 is a photomicrograph showing healing and a dense new dentin bridge following amputation of the pulpal horn of a molar and treatment with Pulpdent Paste. Pulpal curettage is recommended for exposures of the pulpal horns of molars.



Figure PS28
Amputation is preferred in a case such as this.



Figure PS29
Shows healing following amputation, the preferred treatment.

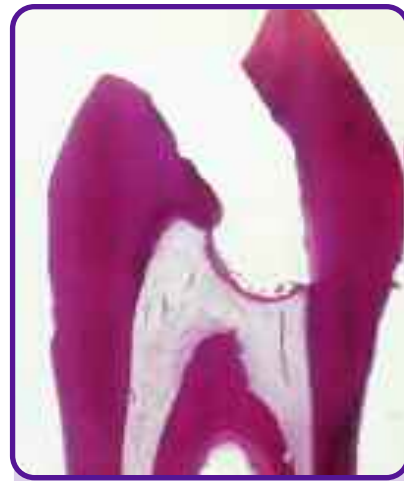

Figure PS30
Pulpal curettage is preferred to pulp capping when treating exposures of the pulpal horns of molars.

REFERENCES

1. Zander HA. Protection of the pulp under silicate cements with cavity varnishes and cement linings. *JADA* 1945;34:811-819.
2. Zander HA, Glenn SF, Nelson CA. Pulp protection in restorative dentistry. *JADA* 1950;41:563-573.
3. Zander HA. The treatment of dentin before insertion of a restoration. *Int Dent J* 1954;4:693-701.
4. Berk H. The effect of calcium hydroxide methyl cellulose paste on the dental pulp. *J Dent Child* 1950;17:65-68.
5. Krakow AA, Berk H, Gron P. Pulpal management in the child and adolescent. In: Hardin JF. *Clark's Clinical Dentistry*. Philadelphia: JB Lippincott, 1994; Vol 2, Chap 9:1-27.
6. Stanley HR, White CL, McCray L. The rate of tertiary (reparative) dentin formation in the human tooth. *Oral Surg* 1966;21:180-189.
7. Mjor IA. Histological studies on human coronal dentin following the insertion of various materials in experimentally prepared cavities. *Arch Oral Biol* 1967;12:441-452.
8. Stanley HR. *Human pulp response to operative dental procedures*. Gainesville FL, Storter Printing Company, 1976.
9. Avery JK. Mechanism of reparative dentin formation and pain. In Grossman L (ed), *Mechanism and Control of Pain*, New York, Mason Publishing, 1979.
10. Levine M. The role of calcium hydroxide and cyanoacrylate in the pulpotomy procedure - an investigation into the reparative process following pulpotomy. Thesis - Harvard/Forsyth Endodontic Program, 1972.
11. Marzouk MA, Van Huysen G. Pulp exposure without hemorrhage. *J Dent Res* 1966;45(2):405.
12. Berk H. Pulp Capping: Re-evaluation of criteria based on clinical and histological findings. *Int Dent J* 1963;13:577.
13. Berk H, Stanley, HR. Pulp healing following capping in human sound and carious teeth. *J Dent Res* 1958;37:66.
14. Cox CF, Bergenholtz, Heys DR, et al. Pulp capping of dental pulp mechanically exposed to microflora: 1-2 year observation of wound healing in the monkey. *J Oral Path* 1985;14:156-168.
15. Berk H, Krakow AA, Stanley HR. Clinical situations in which amputation is preferred to pulp capping because of biologic considerations. *JADA* 1975;90:801-805.